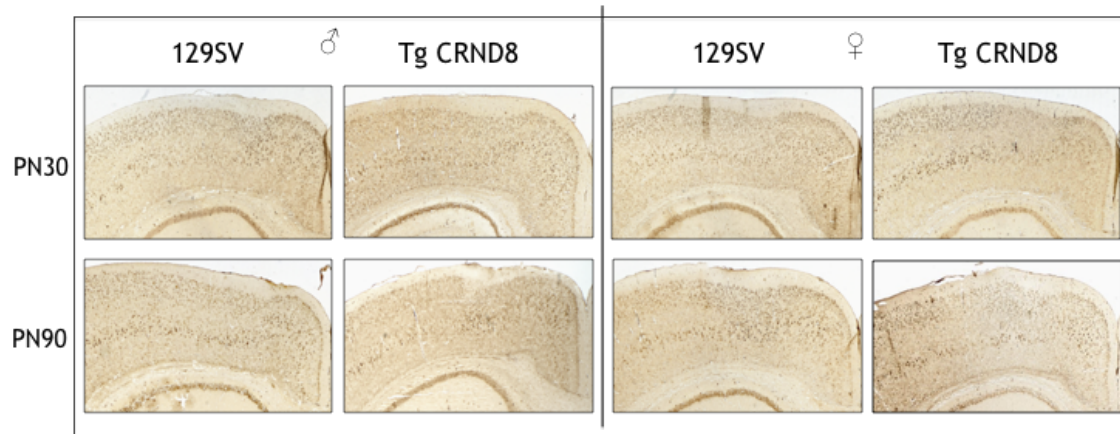
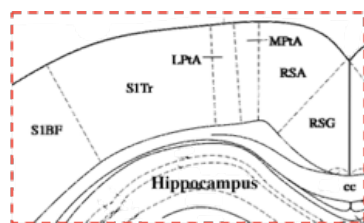
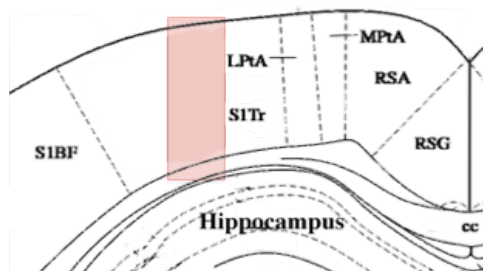
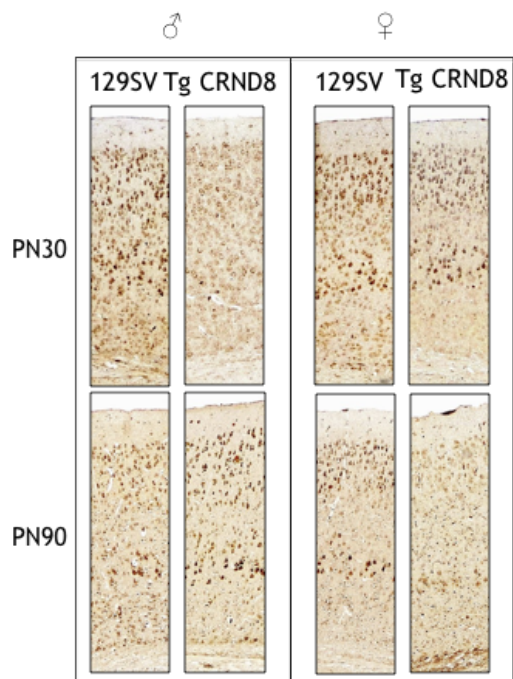


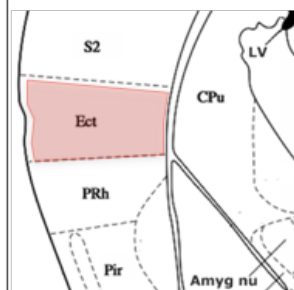
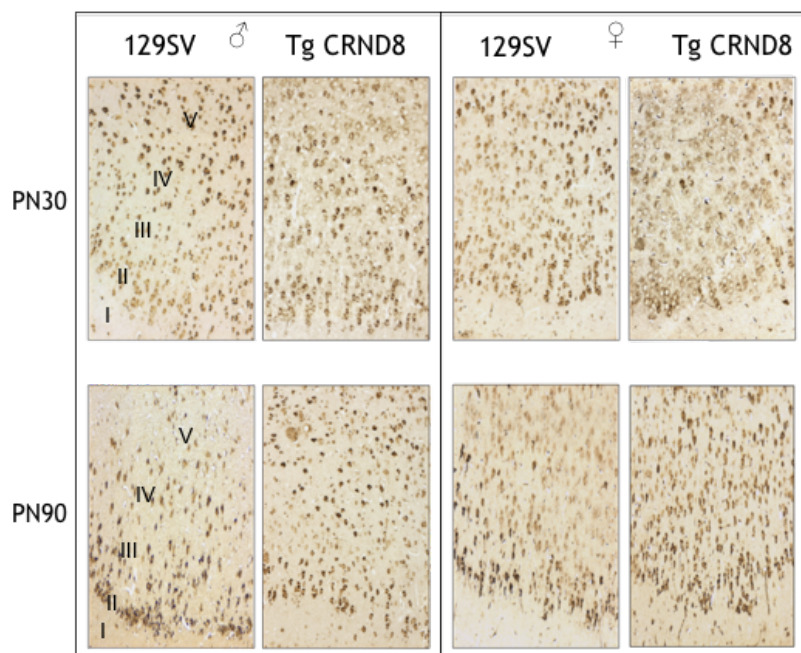
A



B



C



Amyg nu amygdaloid nuclei
 Ect ectothalamic
 Pir piriform cortex
 PRh perirhinal cortex
 Cpu caudate putamen (striatum)
 LV lateral ventricle
 S2 secondary somatosensory cortex