Supporting Information

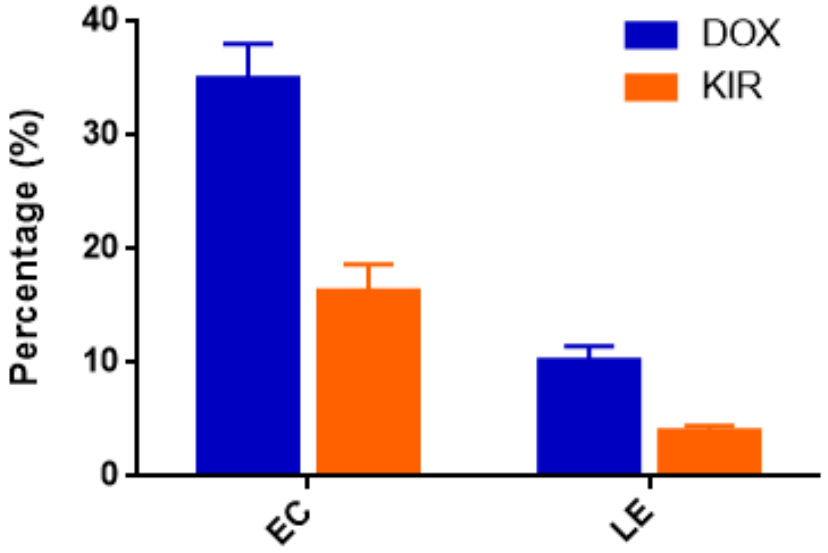

Figure S1. DOX and KIR encapsulation capacity (EC) and loading efficiency (LE) of RM vesicles. Data are mean ± SD (n=3).

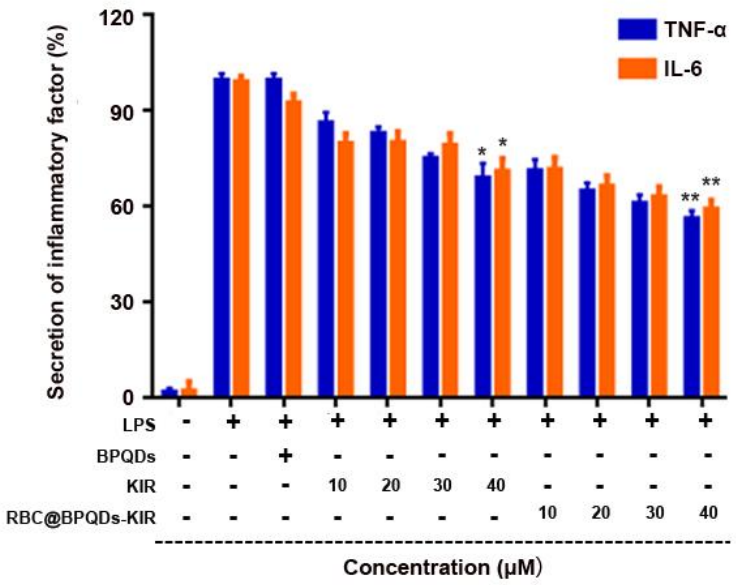

Figure S2. TNF-α and IL-6 secretion at different treatment. The TNF-α and IL-6 secretion of macrophages treated by PBS (negative control) and lipopolysaccharides (LPS) (positive control) was set as 0% and 100%, respectively. Data are mean ± SD (n=3). *indicated $p<0.05$ *vs.* LPS. **indicated $p < 0.01$ *vs.* LPS.

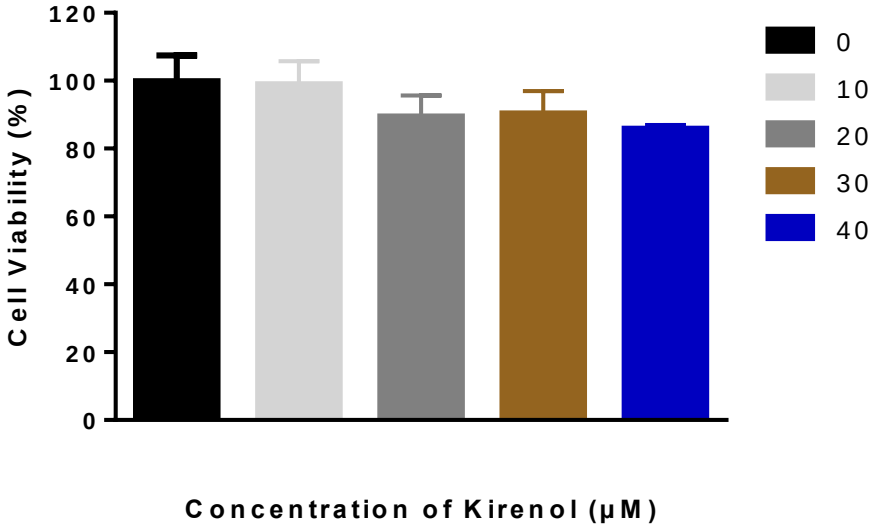

Figure S3. Cell viability of Hela cell treated with different concentration of kirenol. Data are mean ± SD (n=3).

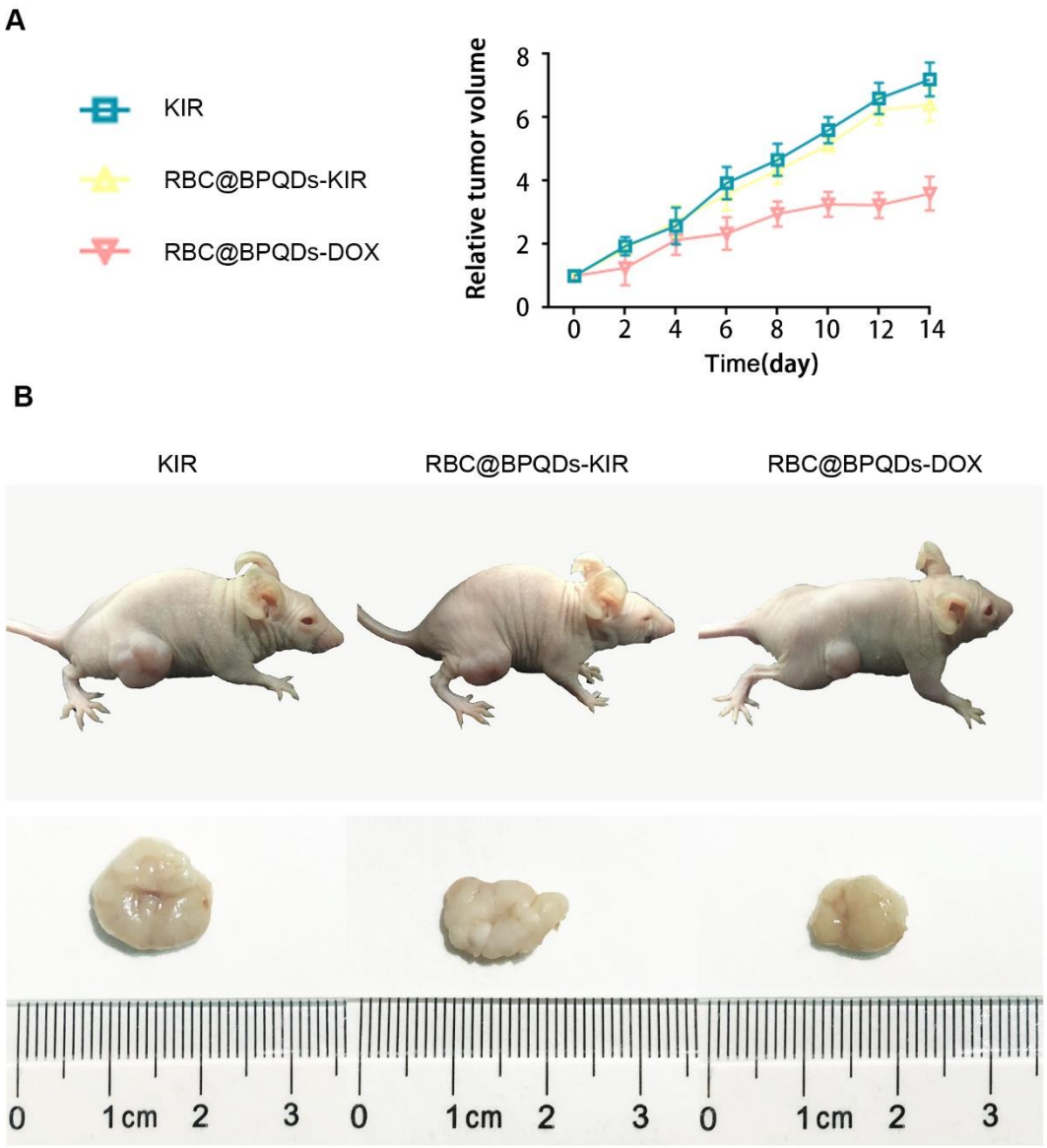

Figure S4. (A) Tumor growth patterns after various treatments. Tumor volumes were normalized to baseline values. （B）Representative images of animals after intravenous injection of different formulations at day 14. Data are mean ± SD (n=3).

	Control	BPQDs	DOX	DOX+KIR	BPQDs -DOX/KIR	RBC@ BPQDs -DOX/KIR
Serum enzyme level						
ALT(U/L)	9.5±0.7	13.0±1.4*	17.0±5.7*	15.5±5.0*	12.5±0.7	8.5±0.7
AST(U/L)	47.0±2.8	78.0±31.1*	84.5±61.5*	124.0±25.5**	71.0±4.2*	57.0±1.4
Urea(mmol/L)	2.0±0.1	1.8±0.1	1.8±0.1	2.9±1.2	1.8±0.4	1.4±0.1
CRE(μmol/L)	6.5±0.7	6.5±0.7	7.5±2.1	6.0±2.8	7.0±1.4	6.5±0.7
Blood cell level						
WBC(10^9/L)	7.5±0.2	5.4±0.8*	1.9±0.1*	2.2±0.1*	0.9±0.2*	2.4±0.2*
RBC(10^{12}/L)	11.0±1.4	10.3±0.1	8.3±0.1	7.4±0.1*	7.4±0.0*	7.2±0.2*
HGB(g/dL)	14.6±0.4	15.3±0.2	13.6±0.1	11.7±0.1*	12.3±0.3	11.5±0.3*
HCT(%)	48.9±2.6	51.3±0.3	38.2±1.0*	36.2±0.2*	34.4±0.6*	34.6±3.4*
PLT(10^{11}/L)	8.4±0.3	7.7±1.3	8.3±0.1	7.1±0.6	8.5±0.4	8.3±0.1

Table S1. The blood cell counts and the serum biochemical substance analysis of tumor bearing mice after treated. Data are mean ± SD (n=3). *indicated $p<0.05$ *vs.* Control. **indicated $p < 0.001$ *vs.* Control.

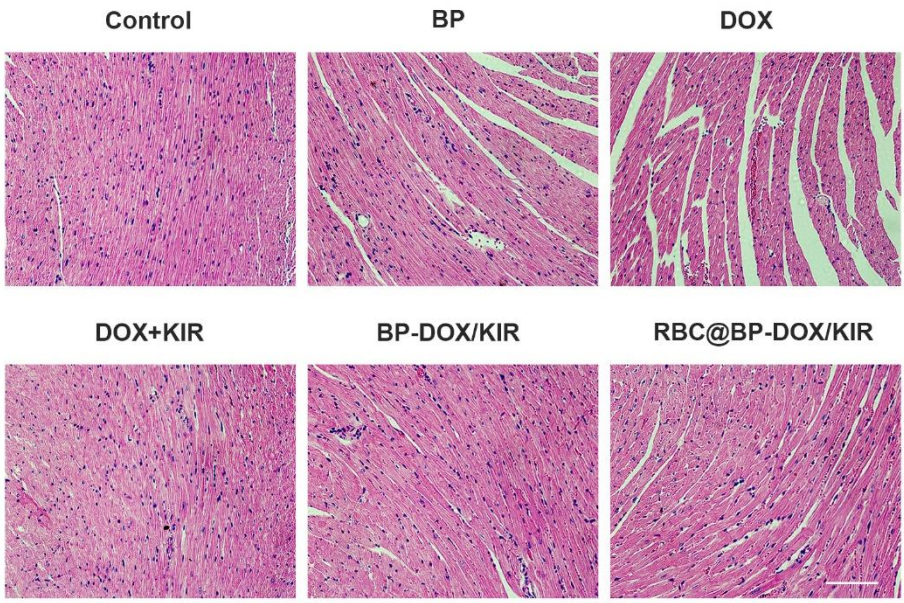

Figure S5. The Histological observation of the heart tissues after the treatment with different formulations. The heart sections were stained with hematoxylin and eosin (H&E). Scale bar: 10μm

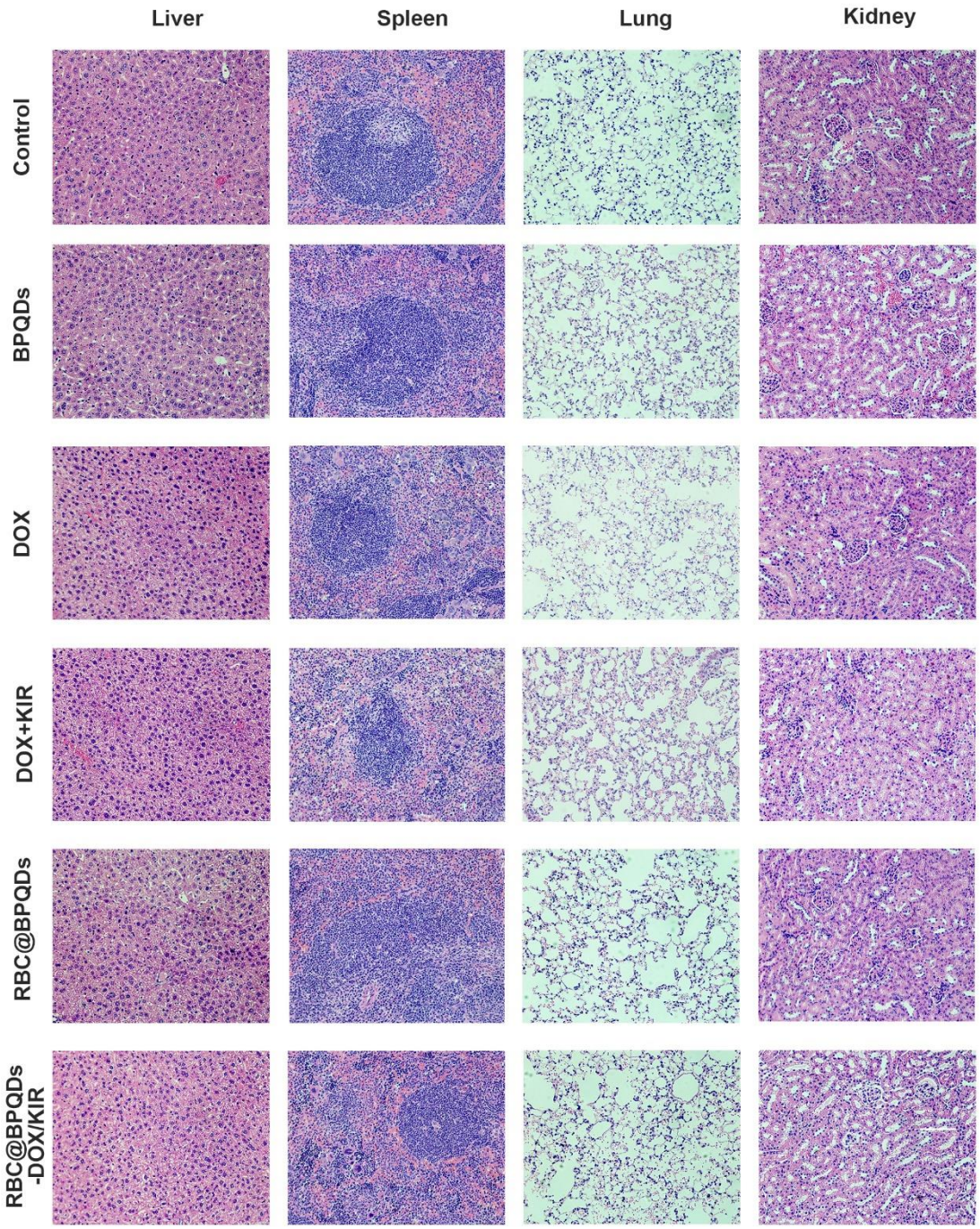

Figure S5. Histological observation of other organs collected from the Hela tumor-bearing mice after the treatment. The major organ sections were stained with hematoxylin and eosin (H&E). Scale bar: 10μm

.