

Tumor necrosis correlates with PD-L1 and PD-1 expression in lung adenocarcinoma

Lilla Reiniger, Vanda Téglási, Orsolya Pipek, Livia Rojkó, Tibor Glasz, Attila Vágvolgyi, Ilona Kovalszky, Márton Gyulai, Zoltán Lohinai, Erzsébet Rásó, József Tímár, Balázs Döme, Zoltán Szállási, Judit Moldvay

Supplementary figure 2. Exemplary images of PD-L1/PD-1 immunostainings.

A: PD-L1 expression of tumor cells with 1, 5 and 50% cut-off levels.

B: PD-L1 expression of immune cells with 1, 5 and 10% cut-off levels.

C: PD-1 expression of immune cells with 1, 5 and 10% cut-off levels.

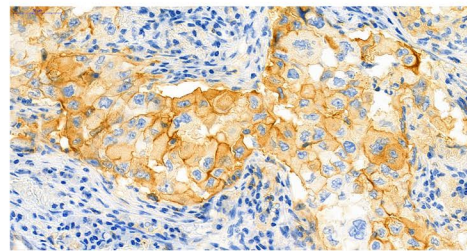
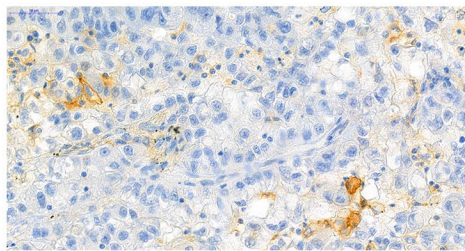
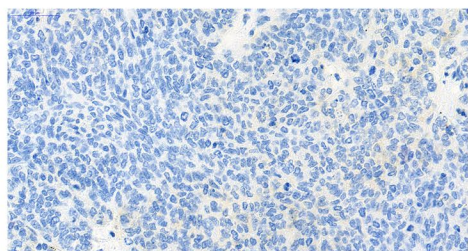
(400x magnification, scale bars represent 50µm)

<1%

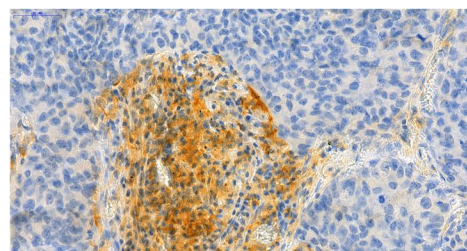
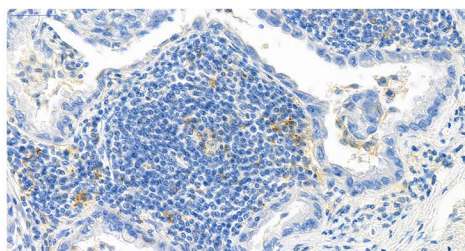
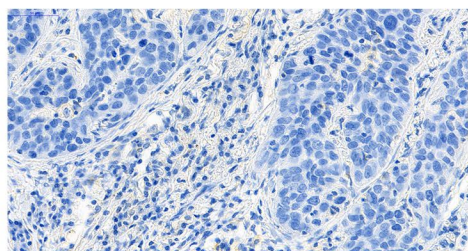
5%

>50% / >10%

A



B



C

