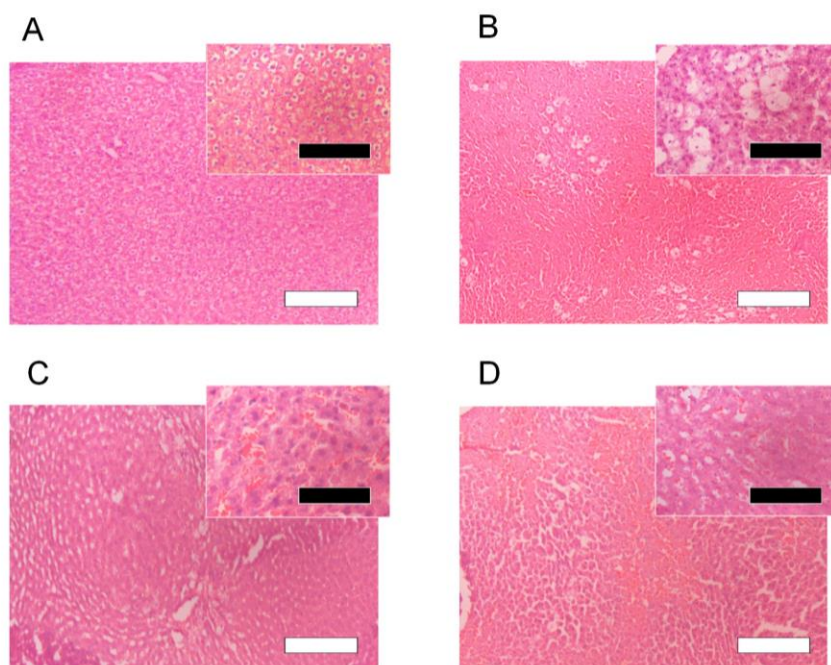


## SUPPLEMENTAL DATA



**Figure S1.** Histological features of liver sections after CCl<sub>4</sub> challenge with or without the oral administration of crystalline CAR (10 mg/kg, *p.o.*) or SEDDS-CAR (10 mg-CAR/kg, *p.o.*). (A) Rats treated with corn oil, (B) CCl<sub>4</sub>-treated rats, (C) CCl<sub>4</sub>-treated rats with crystalline CAR, and (D) CCl<sub>4</sub>-treated rats with SEDDS-CAR. The insets highlight the histological changes of liver tissues. White and black bars represent 250 and 100  $\mu$ m, respectively.