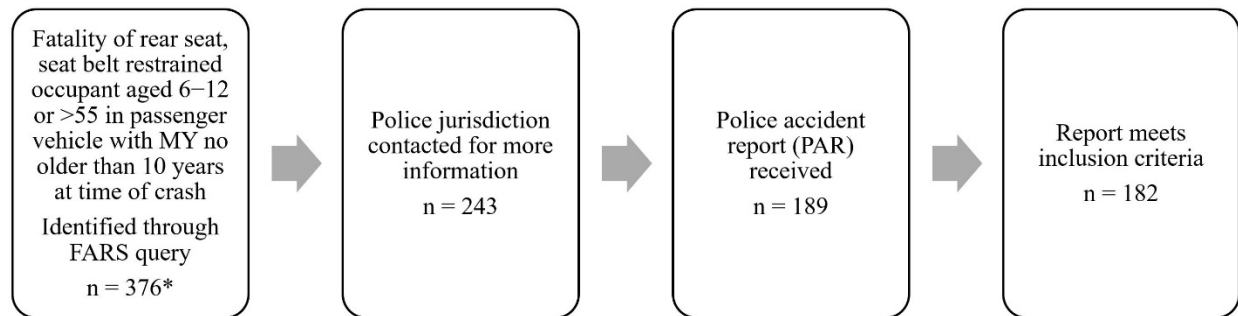


APPENDIX A: Supplemental Figures

Figure A1 outlines the data collection process for cases identified in FARS. For this study, a *crash* is defined as an impact between the occupant's vehicle and a crash partner, and a *case* represents a single decedent of interest. In total, 376 cases were identified using a query in FARS. Of these, police jurisdictions were contacted for 243. Crash information was received from jurisdictions for 189 cases. It was determined that seven received cases did not meet the inclusion criteria, resulting in 182 final cases. Some crashes resulted in more than one decedent who met the criteria. A frontal impact was the most severe event in 81 cases, forming the data set for the current study.



*Census of all such crashes for 2014–15

MY=model year

Figure A1. Collection process for police accident reports (PAR) for fatalities identified in FARS.




Figure A2. A head-on collision between this 2002 Suzuki Vitara and a passenger car resulted in an estimated 19 km/h delta V (from crash reconstruction) for the Vitara. A 64-year-old female in the left rear seat was fatally injured with AIS 3+ chest and head injuries.



Figure A3. A head-on collision between this 2015 Chevrolet Impala and a passenger car resulted in a 44 km/h longitudinal delta V (from EDR) for the Impala. Both rear-seat occupants, an 84-year-old obese male in the left rear and a 79-year-old obese female in the right rear, were fatally injured with chest and spine injuries.

APPENDIX B – Brief Summaries of Cases with Neck Injury

CHOP #81



Case vehicle: Passenger car

Principal crash partner: Heavy truck/vehicle

Occupant age: 77

Occupant sex: F

Restraint: Lap/shoulder

Seat position: 23

Injuries: Subarachnoid and intraventricular hemorrhage due to acute head trauma (COD), multiple left facial fractures, left-eye trauma, cervical fractures, left-pelvic fractures, diaphragmatic injury, retroperitoneal hemorrhage.

Other occupants: One of other three occupants killed—not stated which in report.

CHOP #82



Case vehicle: Passenger car

Principal crash partner: Wood utility pole

Occupant age: 9

Occupant sex: F


Restraint: Lap/shoulder

Seat position: 21

Injuries: Decedent suffered nonspecific neck injury.

Other occupants: All other occupants survived with incapacitating injuries. Fatally injured occupant was the only one properly restrained.

CHOP #96



Case vehicle: Passenger car

Principal crash partner: Passenger car

Occupant age: 8

Occupant sex: F


Restraint: Lap/shoulder

Seat position: 21

Injuries: Massive neck and chest trauma.


Other occupants: Other rear passenger was fatally injured. Driver and front-seat passenger sustained B-type injuries.

CHOP #105



Case vehicle: Passenger car
Principal crash partner: SUV
Occupant age: 78
Occupant sex: F
Restraint: Lap/shoulder worn incorrectly
Seat position: 23
Injuries: Severed brainstem (two locations); severed spine at T12; hinged skull fracture; 10 broken ribs
Other occupants: Driver and front seat passenger survived.

CHOP #109



Case vehicle: SUV
Principal crash partner: Pickup
Occupant age: 77
Occupant sex: F
Restraint: Lap/shoulder
Seat position: 23
Injuries: Multiple blunt force injuries with multiple contusions and abrasions of neck and torso. C1/C2 fracture with complete atlanto-occipital dislocation.
Other occupants: Driver, front-seat passenger, and middle and left rear-seat passengers survived with minor injuries.

CHOP #110



Case vehicle: SUV
Principal crash partner: SUV
Occupant age: 60
Occupant sex: F
Restraint: Lap/shoulder
Seat position: 23
Injuries: Atlanto-occipital dislocation, subarachnoid hemorrhage, sternum and rib fractures, bilateral hemothoraces, lacerations of liver and mesentery, abrasions and contusions of hand and legs.
Other occupants: Driver survived with visible head injuries, front passenger suffered incapacitating injuries.

CHOP # 123



Case vehicle: SUV

Principal crash partner: Passenger car

Occupant age: 7

Occupant sex: M


Restraint: Lap/shoulder

Seat position: 22

Injuries: Atlanto-occipital dislocation, subarachnoid hemorrhage, bilateral pulmonary contusions, shock bowel, T5 fracture and T4 and T5 flexion injury.

Other occupants: Driver, front-seat passenger, and left rear passenger survived with minor injuries. Right rear passenger survived with major injuries.

CHOP #157



Case vehicle: Passenger car

Principal crash partner: Passenger car

Occupant age: 79

Occupant sex: F


Restraint: Lap/shoulder

Seat position: 21

Injuries: Occipital scalp contusion and right parietal subgaleal hemorrhage, epidural hemorrhage of cervical and proximal thoracic spinal cord, left clavicle and bilateral rib fractures

Other occupants: Right rear passenger (84 year old) was fatally injured, suffering blunt thoracic trauma. Driver and front-seat passenger survived with nonspecific injuries.

CHOP #159



Case vehicle: SUV

Principal crash partner: Pickup

Occupant age: 68

Occupant sex: F


Restraint: Lap/shoulder

Seat position: 21

Injuries: Broken neck and crushed chest

Other occupants: Catastrophic crash. All occupants in vehicle killed. Driver suffered broken neck and crushed chest, other occupants suffered blunt force trauma to the chest.

CHOP #169



Case vehicle: Passenger car

Principal crash partner: Pickup

Occupant age: 7

Occupant sex: F


Restraint: Lap/shoulder

Seat position: 23

Injuries: Atlanto-occipital disarticulation, intracranial subdural and subarachnoid hemorrhage, left-occipital lobe contusion, subscalpular hemorrhage, bilateral pulmonary contusions, bowel injuries.

Other occupants: Left rear occupant also suffered fatal injuries (see below).

CHOP #170



Case vehicle: Passenger car

Principal crash partner: Pickup

Occupant age: 8

Occupant sex: M

Restraint: Lap/shoulder

Seat position: 21

Injuries: Partial brainstem transection, disarticulation of the atlanto-axial joint, intracranial subdural and subarachnoid hemorrhage subscalpular hemorrhage, contusions of epicardium and pulmonary artery and aorta adventitia, bilateral pulmonary contusions and right lung laceration, right clavicular fracture, bilateral perinephric hemorrhage, bilateral hemothoraces and hemoperitoneum, spleen and bowel injuries.

Other occupants: Right rear occupant also suffered fatal injuries (see above).