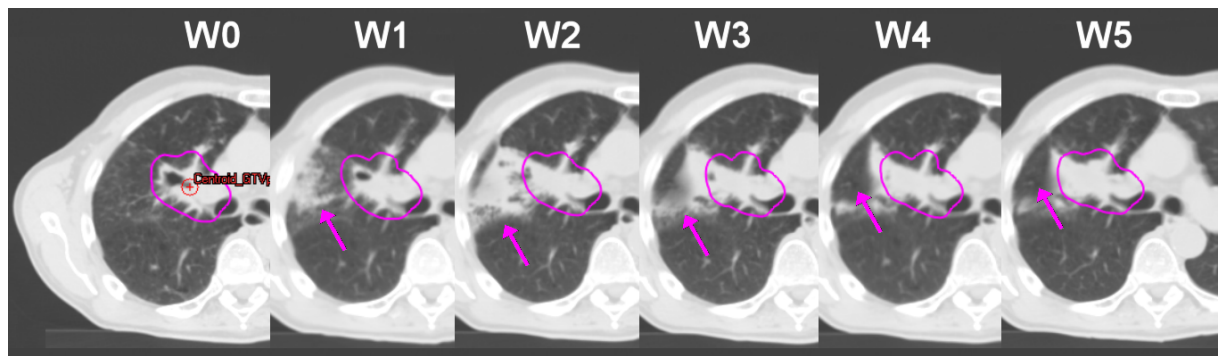


## Supplementary figure



Weekly imaging of a patient who needed re-planning two times due to a dense mass in the lung that changed size, shape, density and location each week.