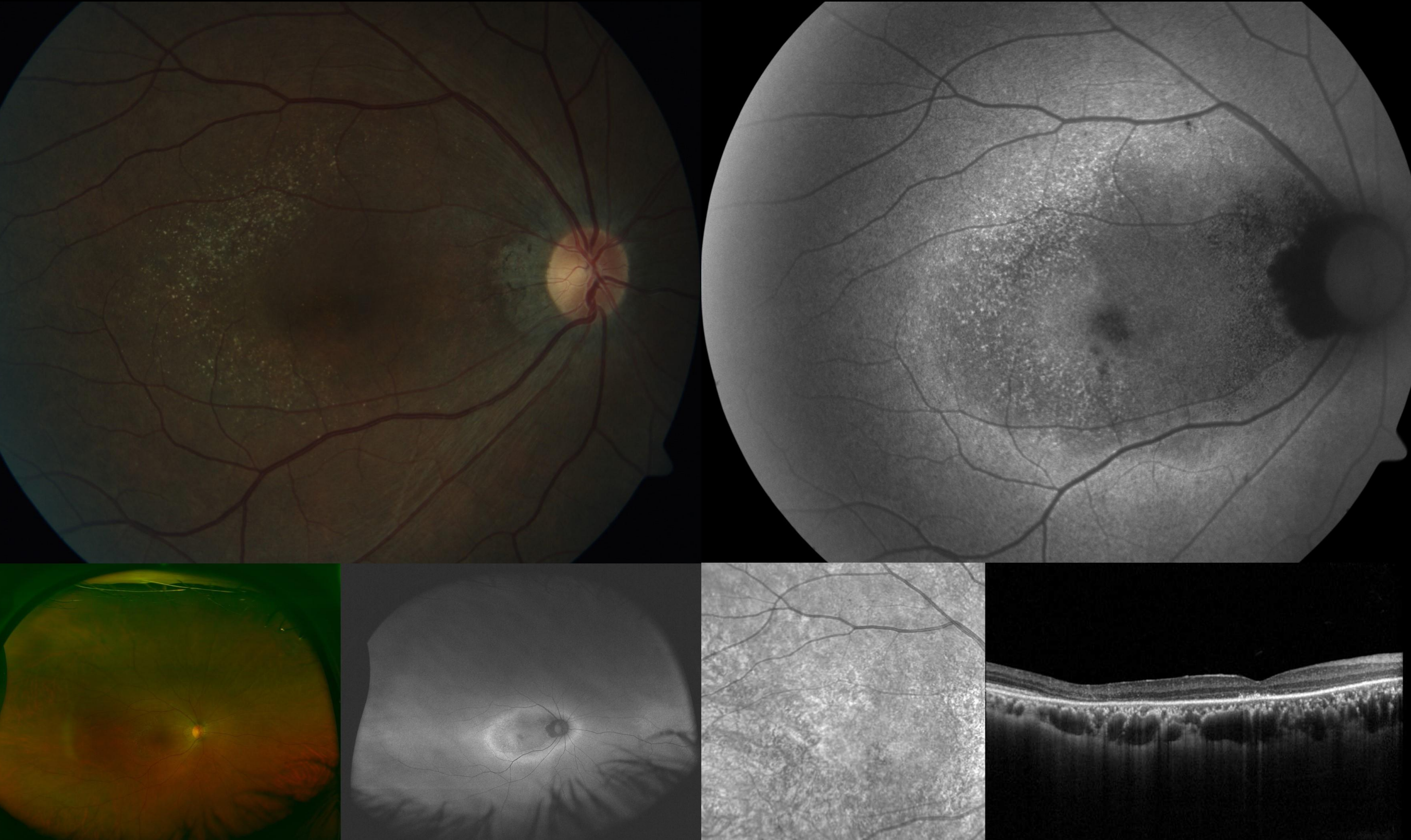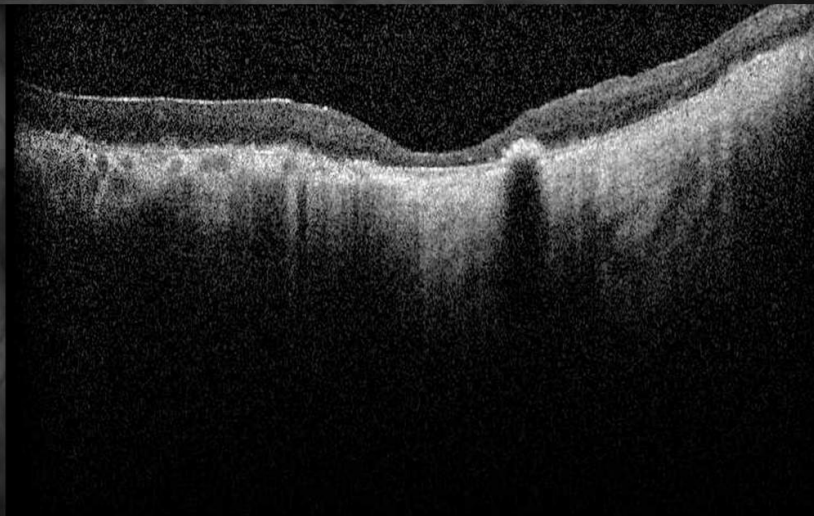
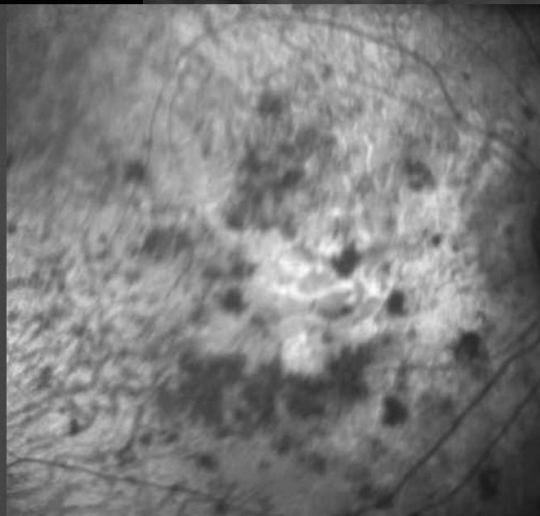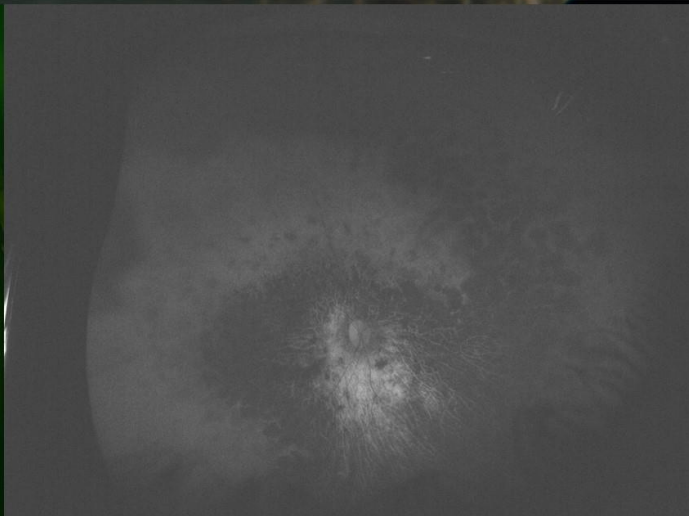
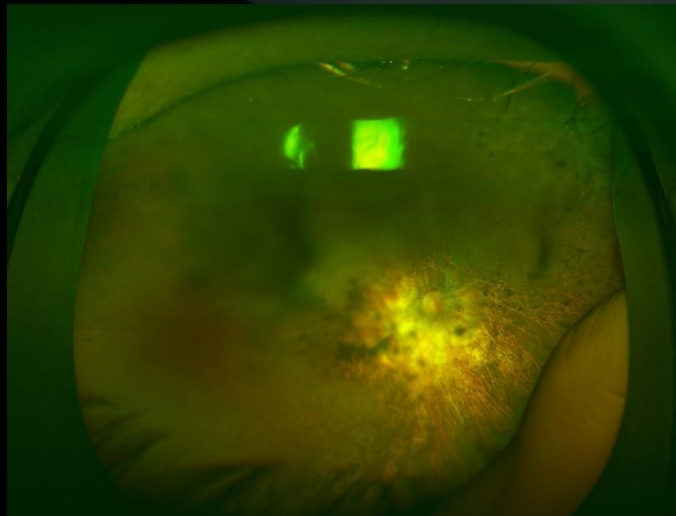
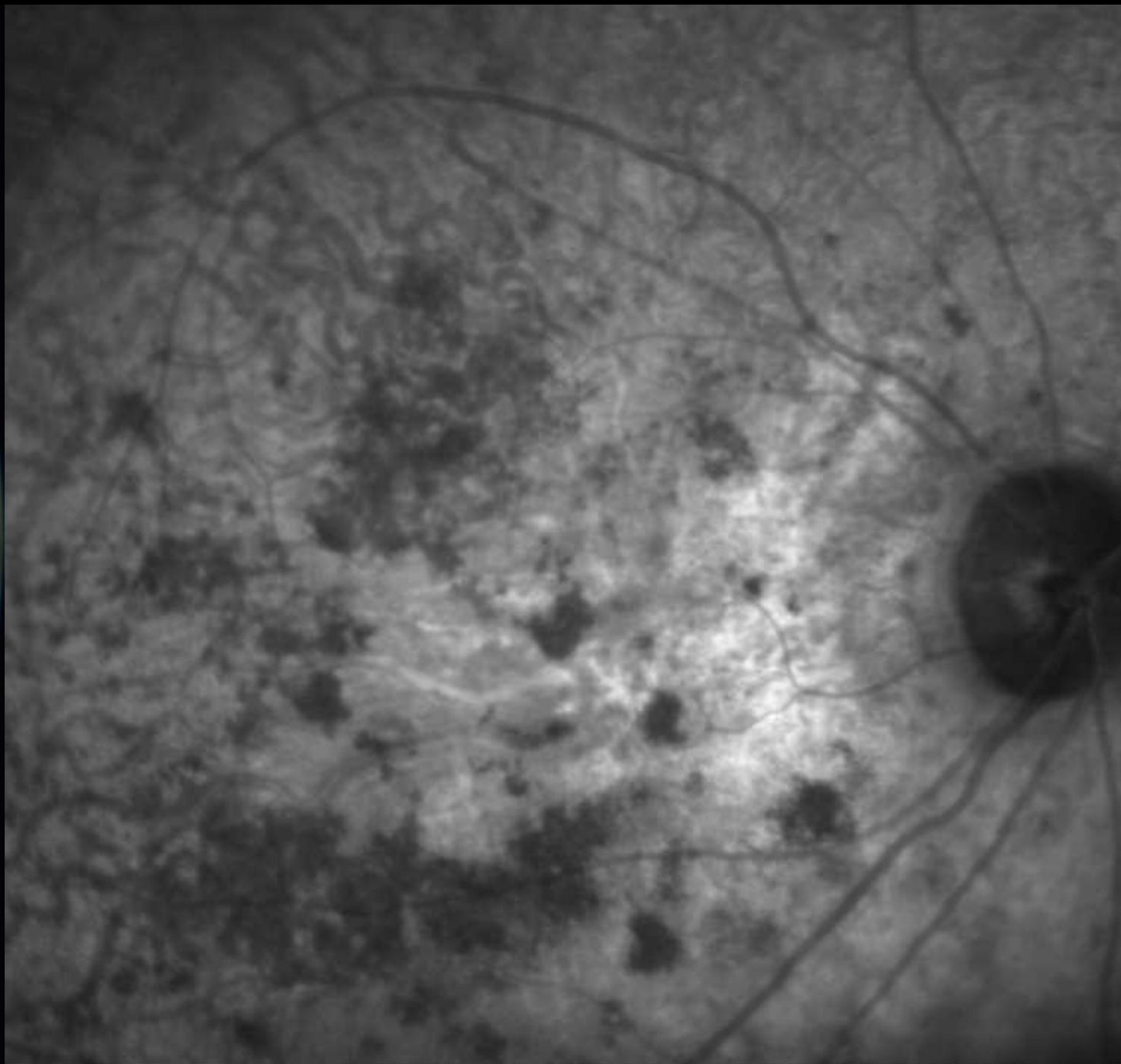
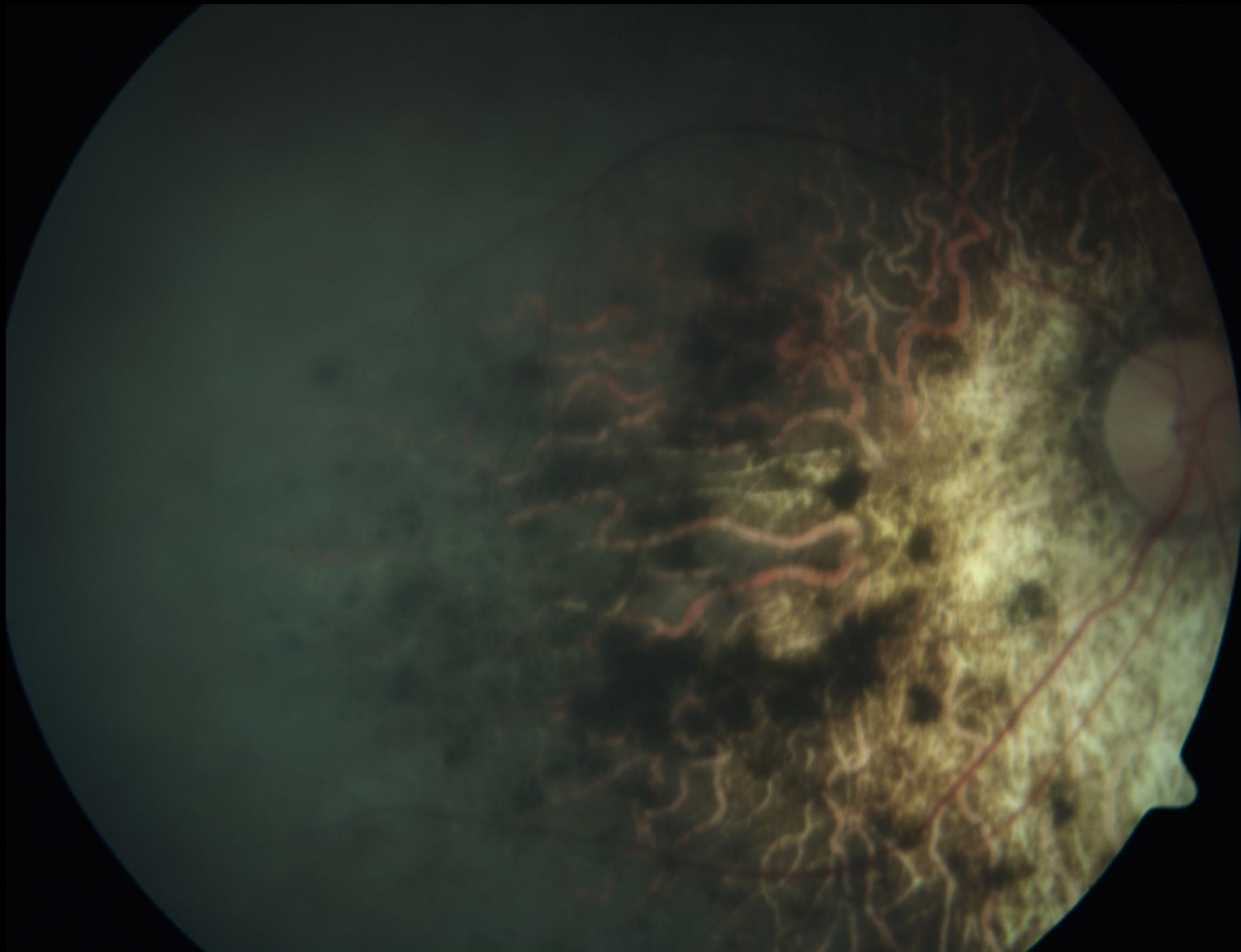


Proband [2.3] (47y; Vsc 20/150, 20/150; insignificant refractive error)



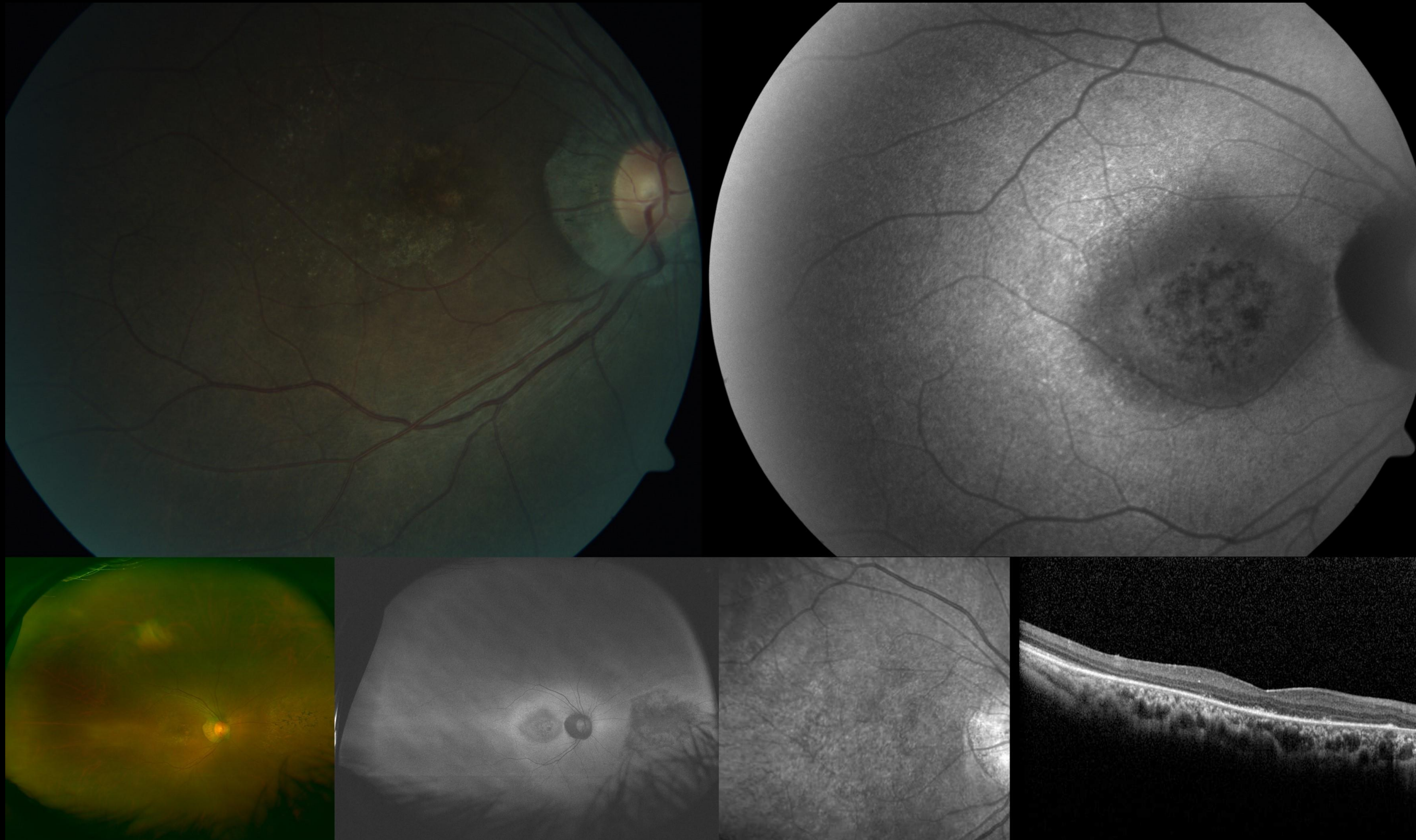


Mother [1.1] (71y; HM, HM; PCIOL both eyes)



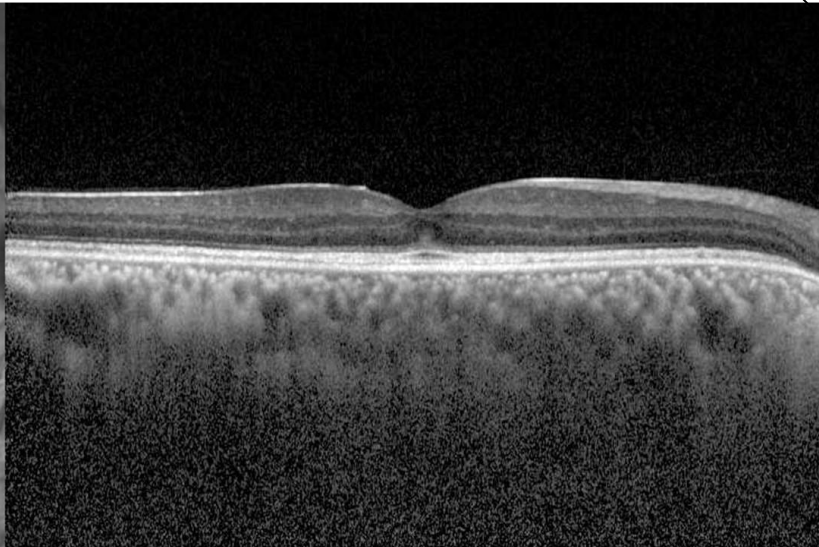
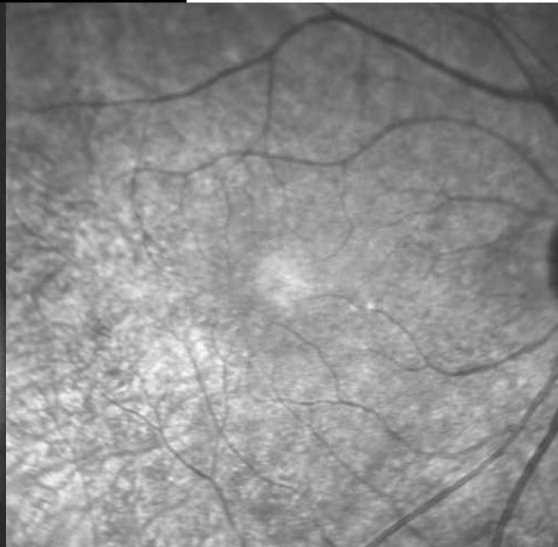
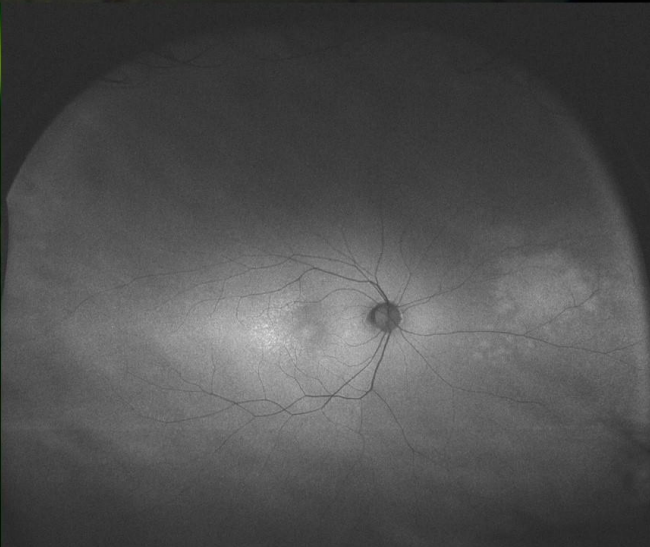
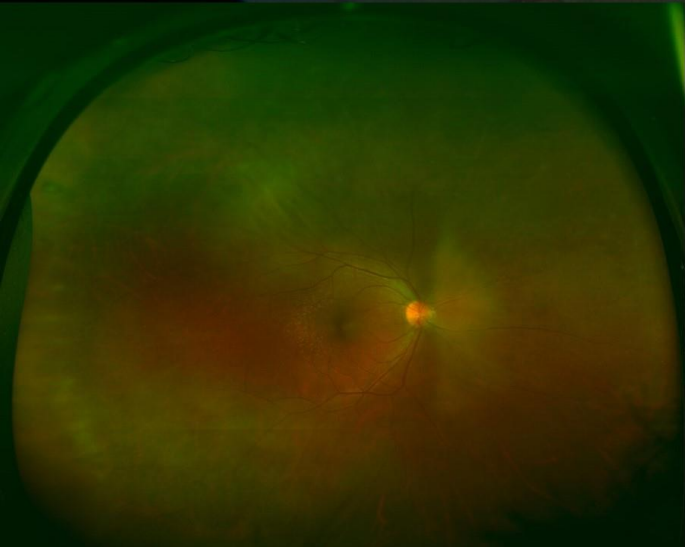
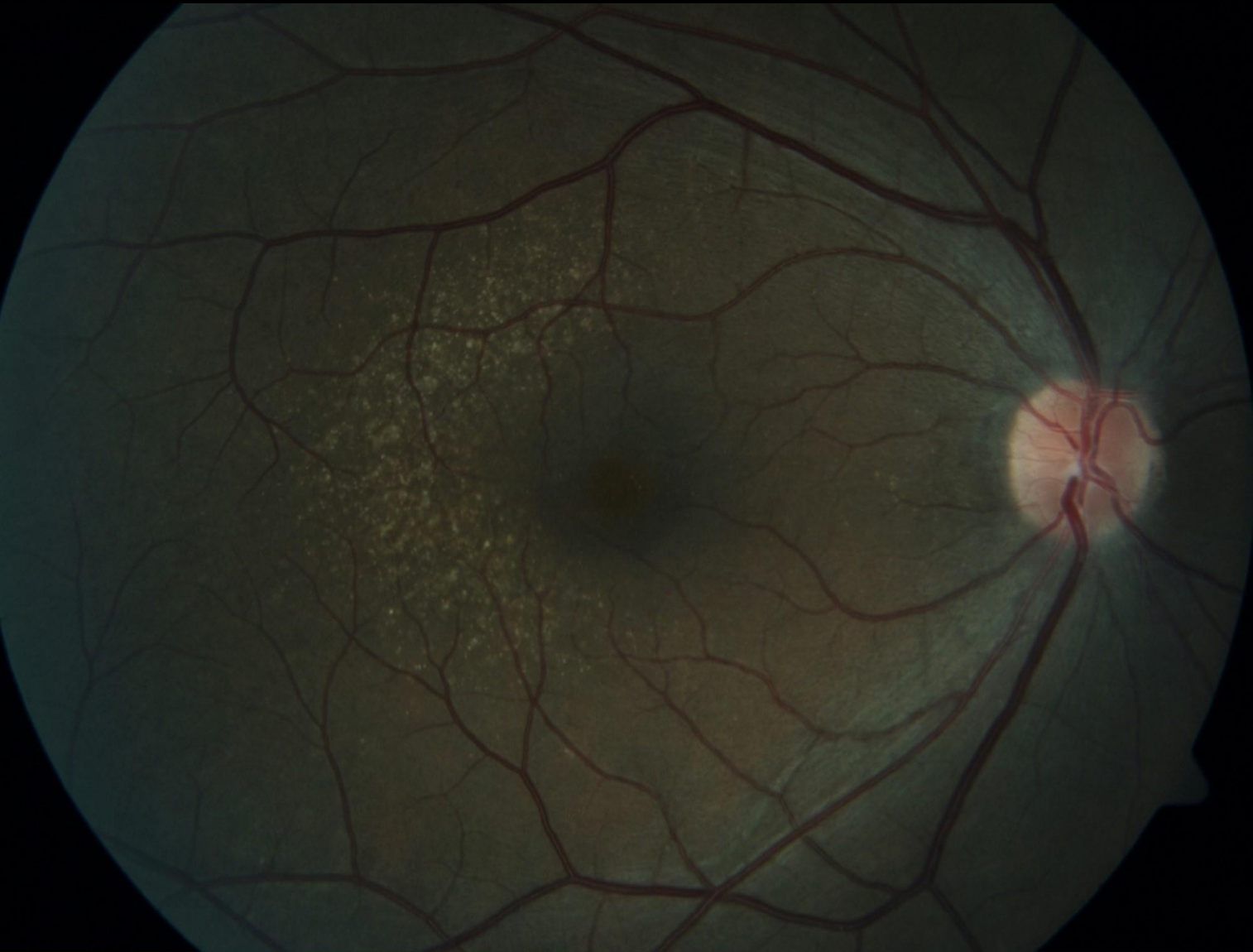
Sister [2.4] (46y; Vsc 20/400, CF; no significant refractive error)



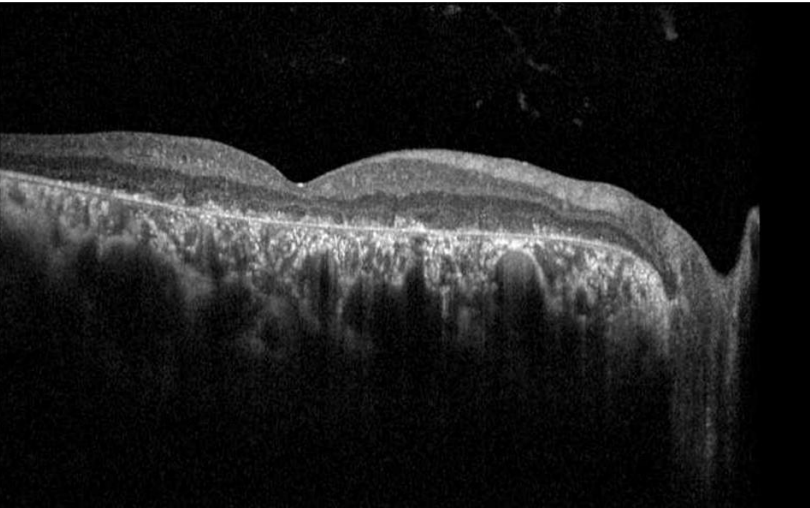
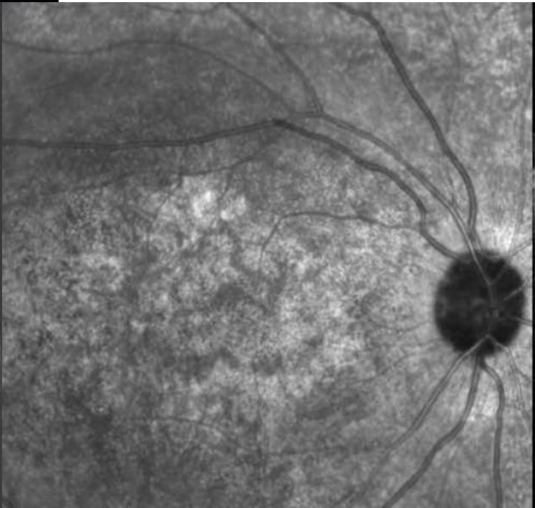
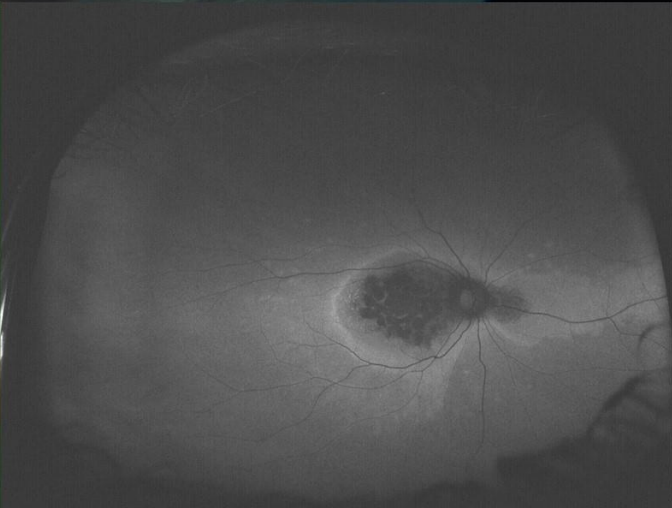
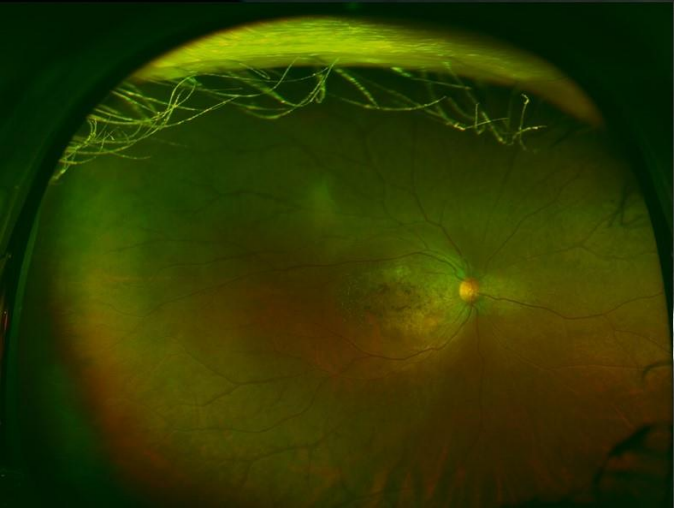

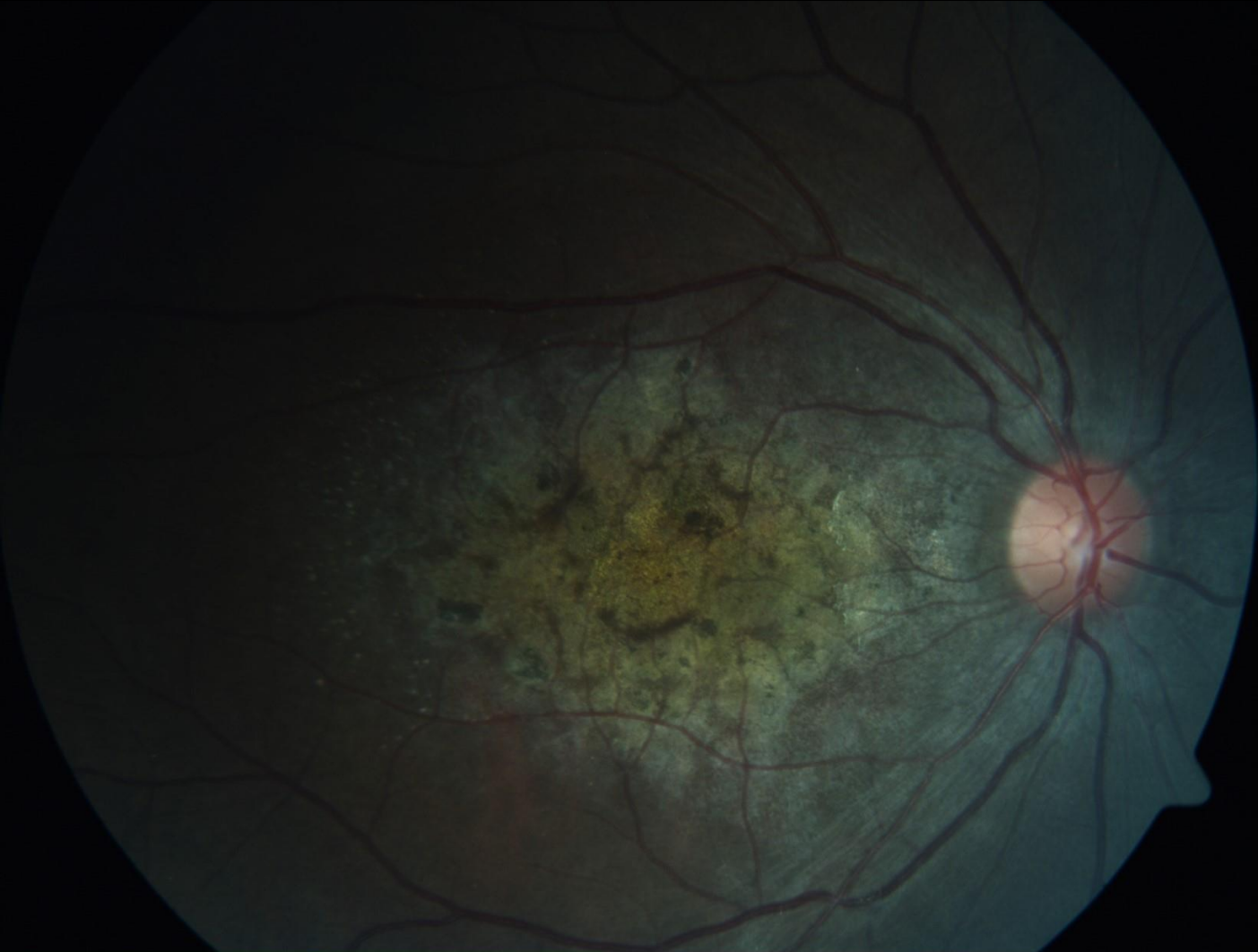


Brother [2.5] (45y; Vsc 20/20, 20/20; no significant refractive error)



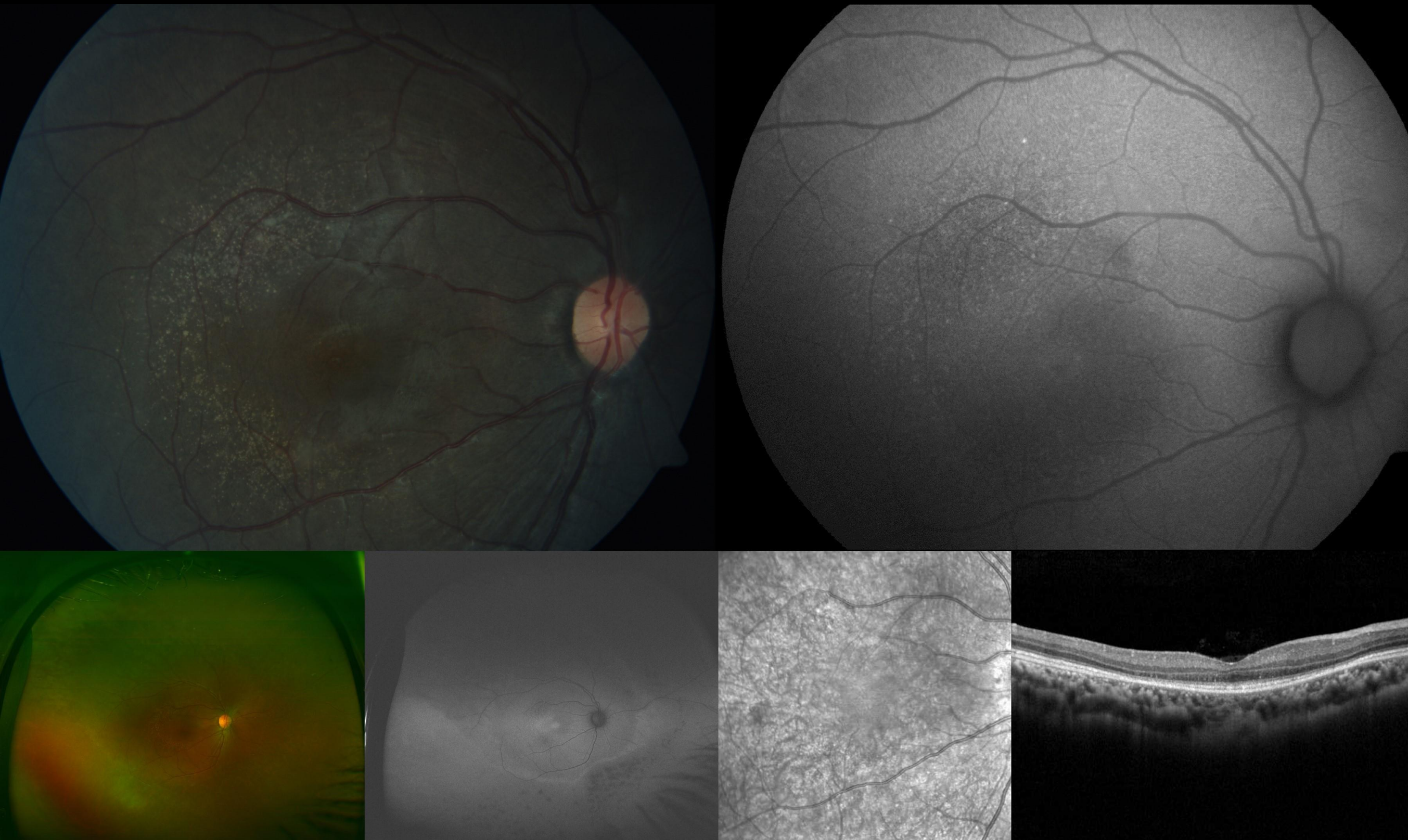


Sister [2.8] (29y; Vsc 20/400, CF; mild astigmatism)



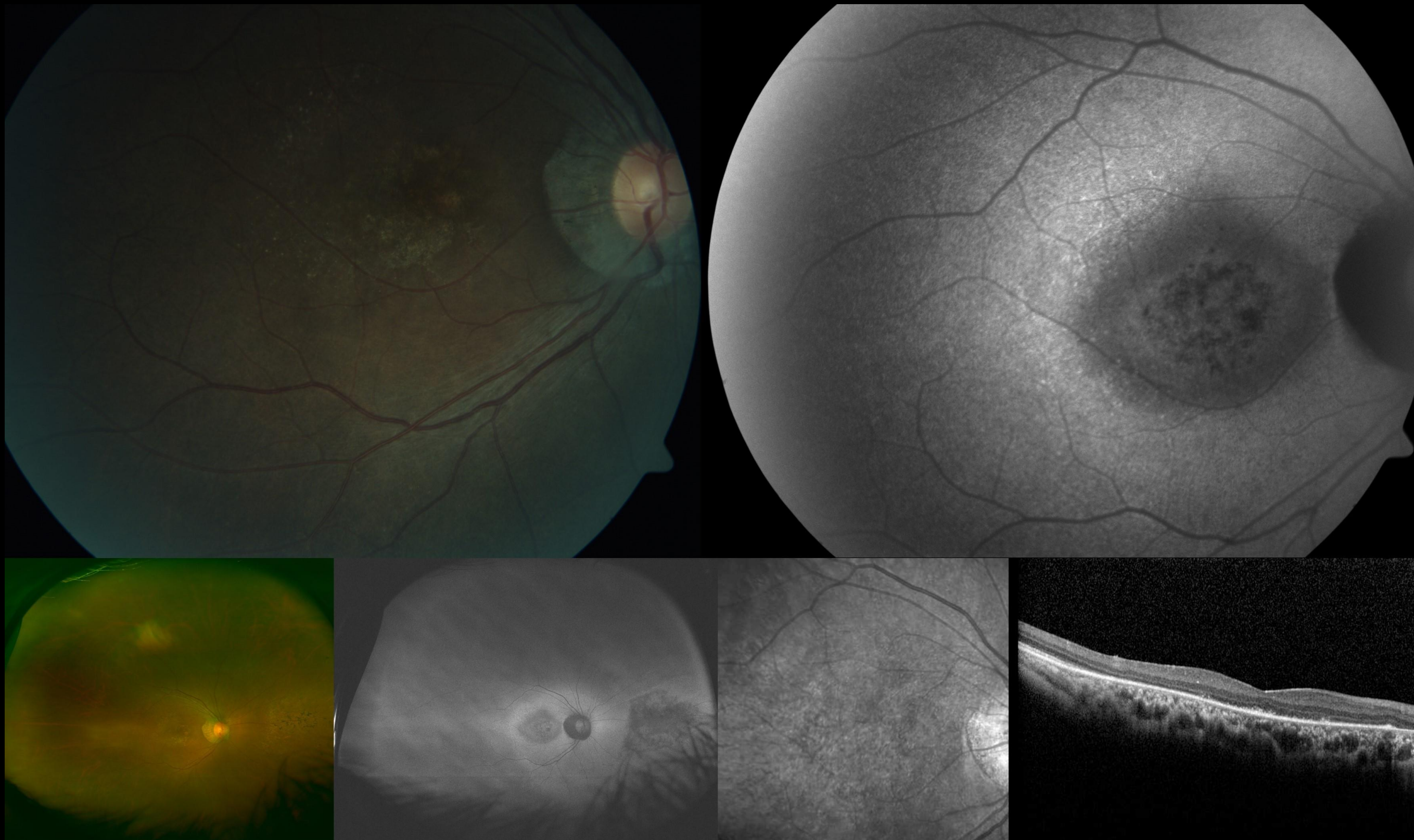


Daughter [3.1] (18y: Vsc 20/25, 20/40; anisohyperopia)





Nephew [3.6] (16y; Vsc 20/25, 20/25; no significant refractive error)





Daughter [3.3] (13y; Vsc 20/25, 20/25; moderate hyperopia)

