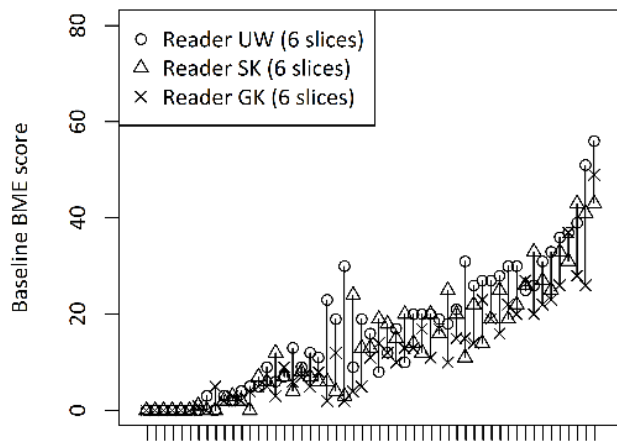
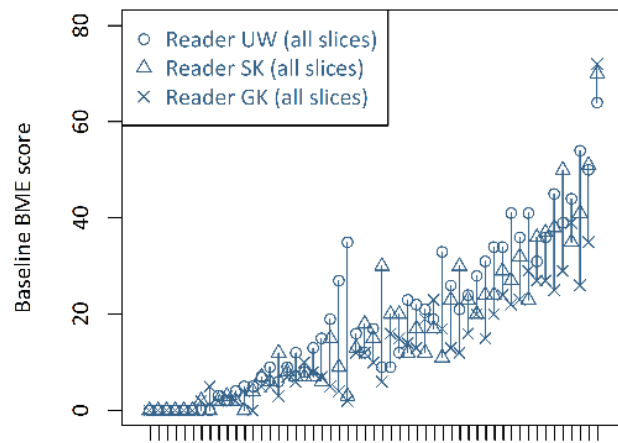


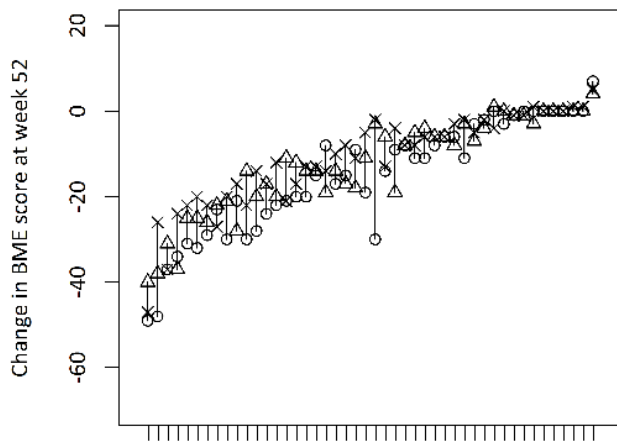
Supplementary figure S1. Bone marrow edema, multiple-reader agreement plots.



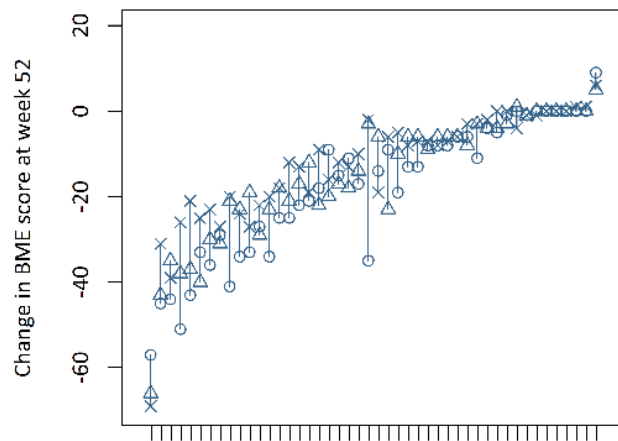
Patients ordered by average baseline BME score



Patients ordered by average baseline BME score



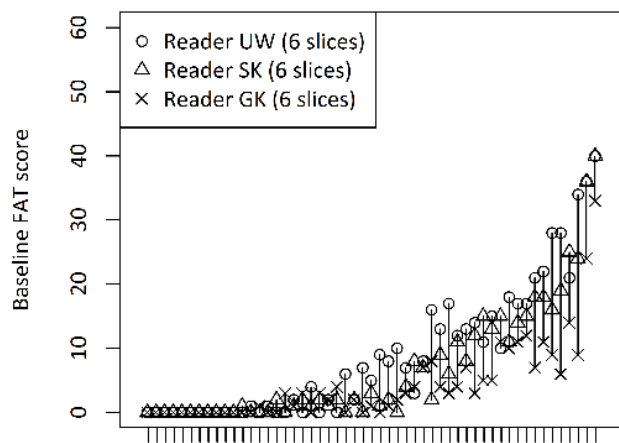
Patients ordered by average change in BME score at week 52



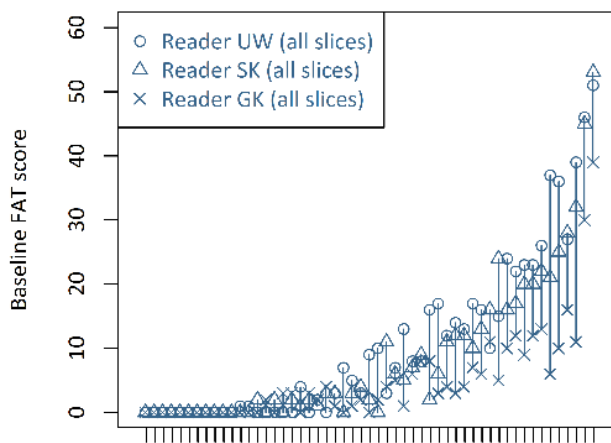
Patients ordered by average change in BME score at week 52

Scoring MRI inflammation and structural lesions in sacroiliac joints of patients with axial spondyloarthritis: assessment of all MRI slices of the cartilaginous compartment versus standardized 6 or 5 slices  
SUPPLEMENTARY MATERIAL 05-MAY-2019

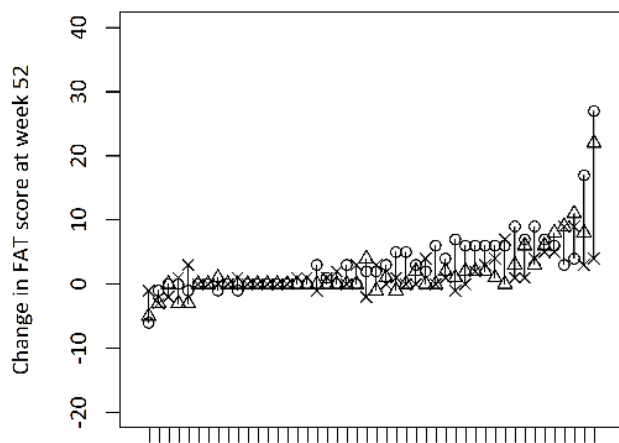
Supplementary figure S2. Fat metaplasia, multiple-reader agreement plots.



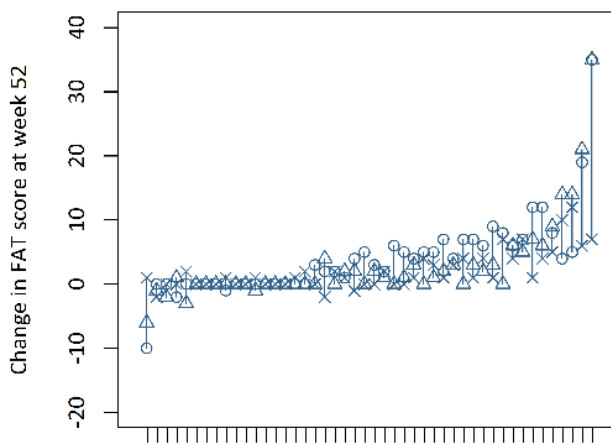
Patients ordered by average baseline FAT score



Patients ordered by average baseline FAT score



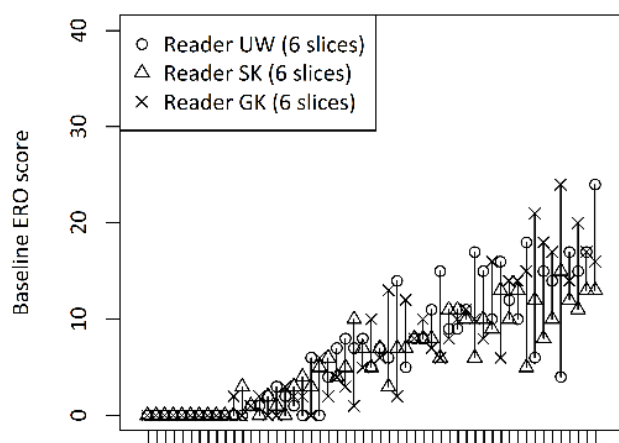
Patients ordered by average change in FAT score at week 52



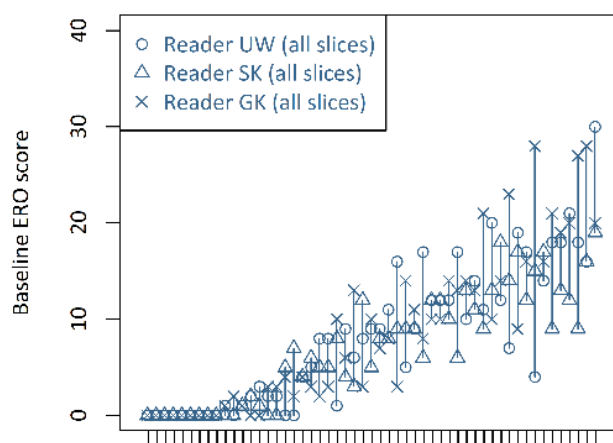
Patients ordered by average change in FAT score at week 52

Scoring MRI inflammation and structural lesions in sacroiliac joints of patients with axial spondyloarthritis: assessment of all MRI slices of the cartilaginous compartment versus standardized 6 or 5 slices  
SUPPLEMENTARY MATERIAL 05-MAY-2019

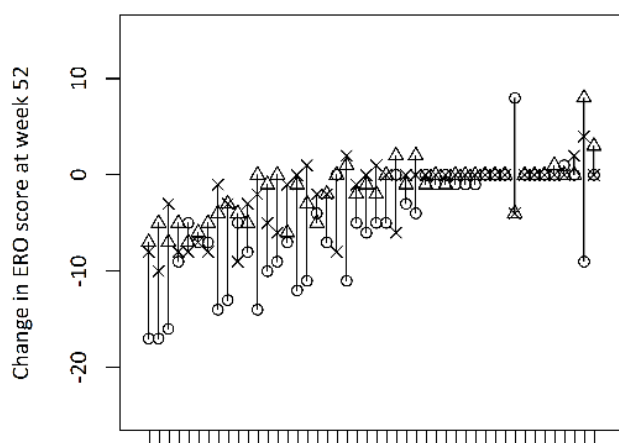
Supplementary figure S3. Erosion, multiple-reader agreement plots.



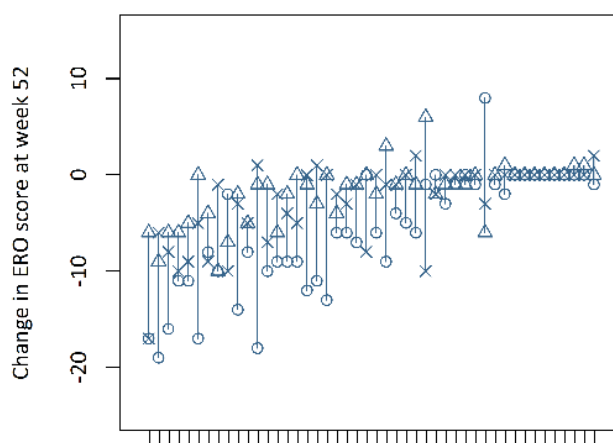
Patients ordered by average baseline ERO score



Patients ordered by average baseline ERO score



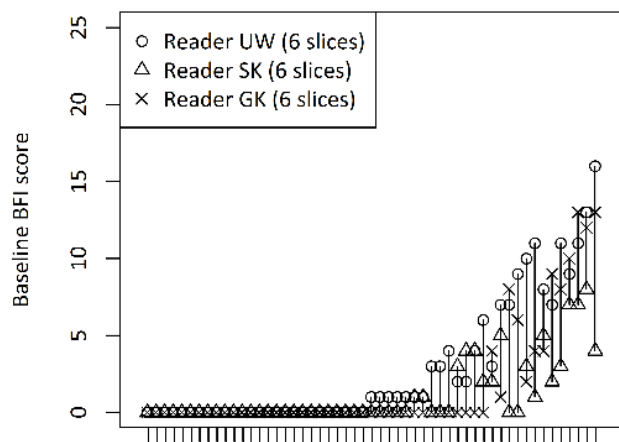
Patients ordered by average change in ERO score at week 52



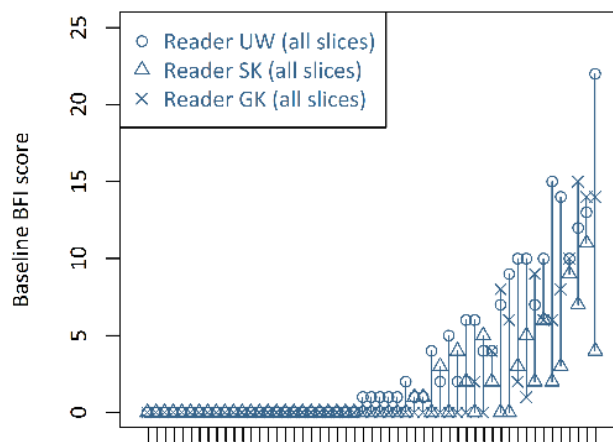
Patients ordered by average change in ERO score at week 52

Scoring MRI inflammation and structural lesions in sacroiliac joints of patients with axial spondyloarthritis: assessment of all MRI slices of the cartilaginous compartment versus standardized 6 or 5 slices  
SUPPLEMENTARY MATERIAL 05-MAY-2019

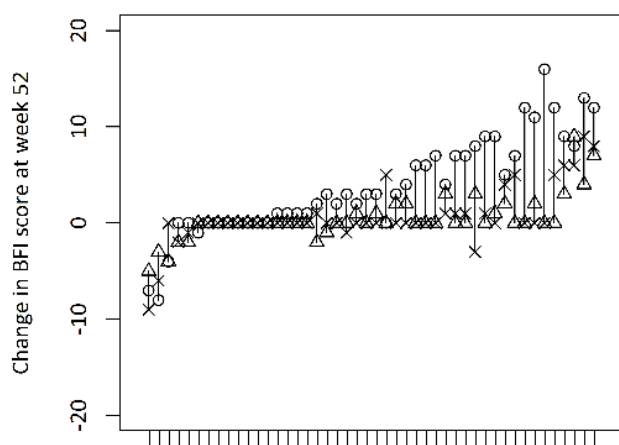
Supplementary figure S4. Backfill, multiple-reader agreement plots.



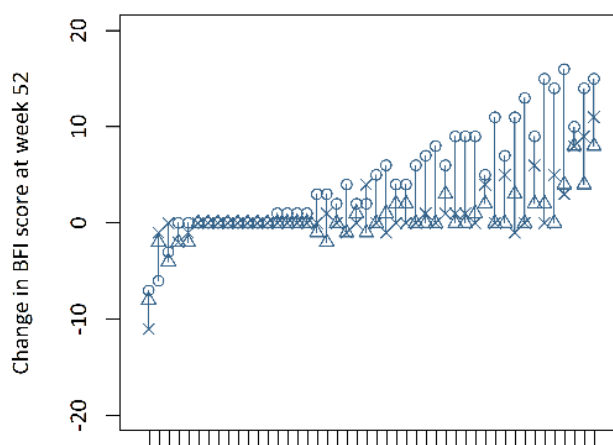
Patients ordered by average baseline BFI score



Patients ordered by average baseline BFI score



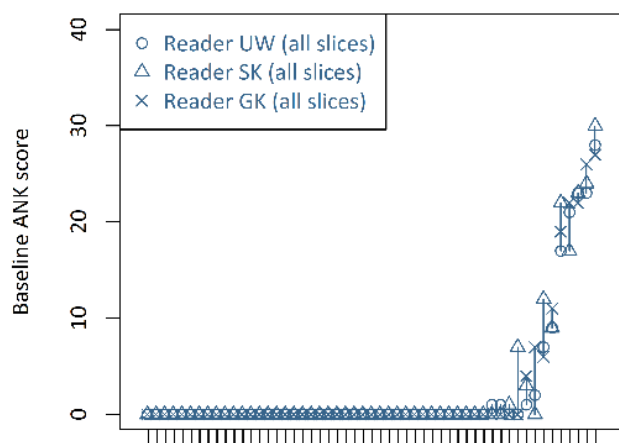
Patients ordered by average change in BFI score at week 52



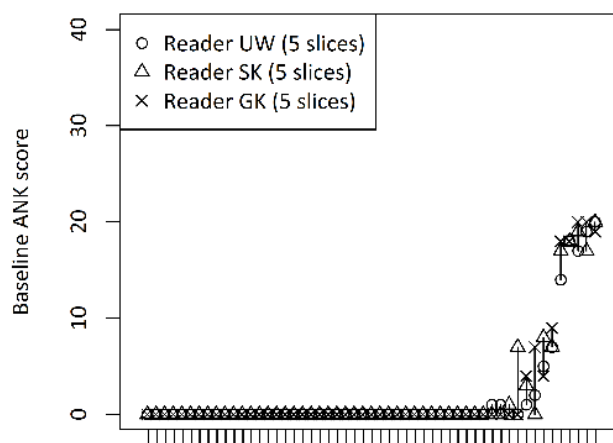
Patients ordered by average change in BFI score at week 52

Scoring MRI inflammation and structural lesions in sacroiliac joints of patients with axial spondyloarthritis: assessment of all MRI slices of the cartilaginous compartment versus standardized 6 or 5 slices  
 SUPPLEMENTARY MATERIAL 05-MAY-2019

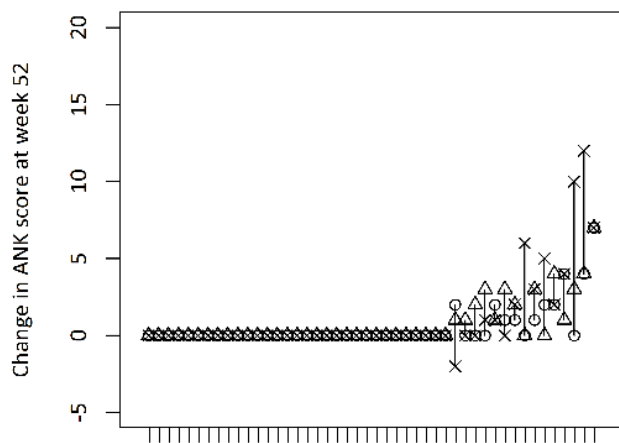
Supplementary figure S5. Ankylosis, multiple-reader agreement plots.



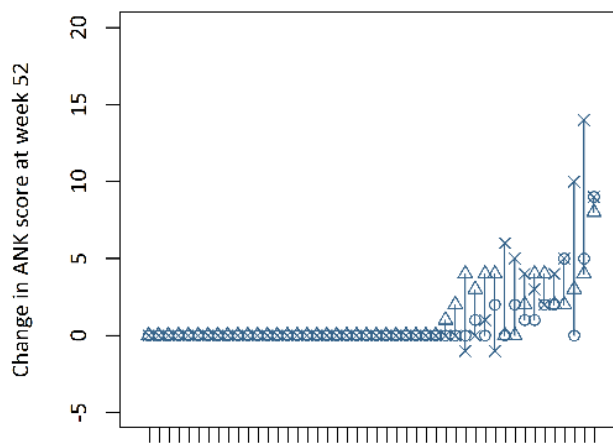
Patients ordered by average baseline ANK score



Patients ordered by average baseline ANK score



Patients ordered by average change in ANK score at week 52



Patients ordered by average change in ANK score at week 52